



Review Article

Microfractured Adipose Tissue Graft (Lipogems) and Regenerative Surgery

Carlo Tremolada*

Image Regenerative Clinic, Milano, Italy

*Corresponding author: Carlo Tremolada, Image Regenerative Clinic, Milano, Italy

Citation: Tremolada C (2022) Microfractured Adipose Tissue Graft (lipogems) and Regenerative Surgery. J Orthop Res Ther 7: 1210 DOI: 10.29011/2575-8241.001210

Received Date: 11 January, 2022; Accepted Date: 25 January, 2022; Published Date: 28 January, 2022

The adipose tissue (subcutaneous and visceral) is the largest organ in our body and has multiple functions both structural and endocrine [1]. It is composed by different cellular components (Figure 1) and has a very rich network of capillary micro vessels that actively participate in the self-repair processes of our organism as quite rich of Pericytes (Figure 2) which represent the precursors of MSCs (mesenchymal stem cells), cellular elements particularly important in reparative mechanisms. Even in past centuries, starting with military doctors in the Napoleonic army, the fat had been used with varying fortunes as a medication; but it is only since the 1980s, with the invention of the liposuction technique and its increasing success, that access to large quantities of tissue with increasingly less invasive techniques has made the lipofilling technique popular, which is nothing more than an autologous transplant of adipose tissue initially aimed at restoring lost volumes (for example in breast reconstruction or facial defects) and later for regenerative purposes (in particular scars and radiodermatitis). Despite having fairly satisfactory clinical outcomes, the major problems related to the classic lipofilling techniques were linked to the excessive variability of the results (volumetric resorption, residual irregularity and fibrosis, unpredictability in the regenerative result) [1].

Human adipose tissue

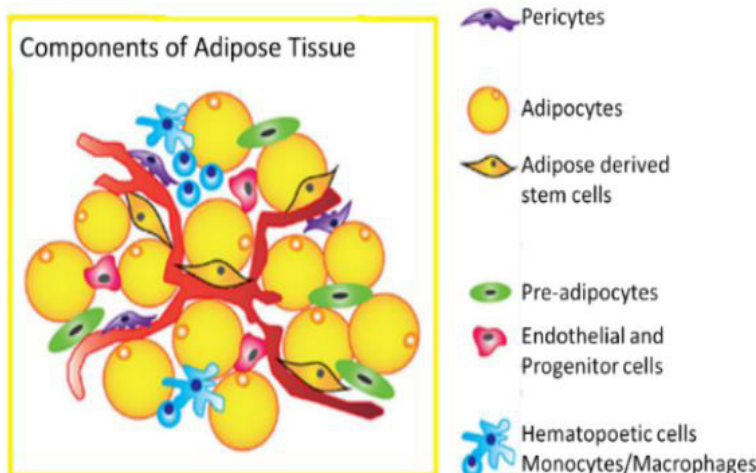


Figure 1: Adipose tissue is composed of many cellular component which can be separated by enzuiymatic treatment. These are found in the Stromal Vascular Fraction (SVF).

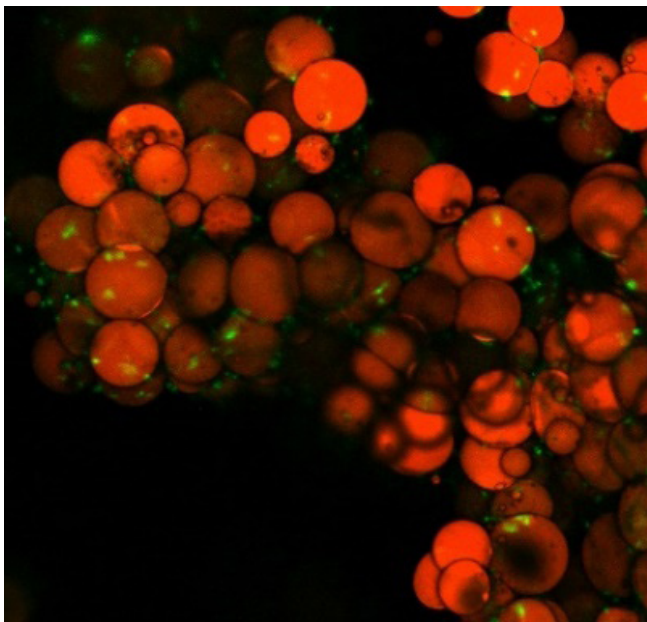
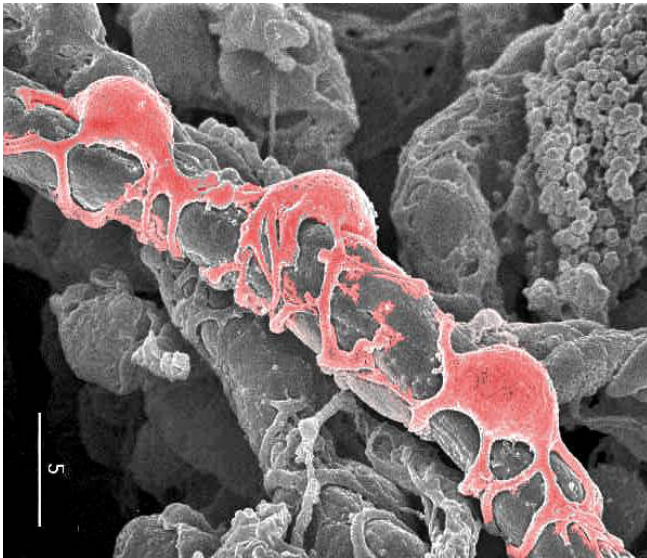


Figure 2: (Above) Pericytes (red cells) sit around the microvessels of all tissues and are the precursor of MSCs. Electronic microscopy showing pericytes in a 5 micron capillary. (Below) Lipogems cluster (adipocytes are in orange and Pericytes are in green) showing the pericytes and the intact microvessels on the surface of the cluster.

Comparison Between Adipose Tissue and Bone Marrow Aspirate as Regenerative Tissue and Source of Biologically and Clinically Active MSC

Adipose tissue and bone marrow have both become the most used tissues for regenerative purposes in the musculoskeletal

system due to the ease and mini-traumatic nature of harvesting and the presence of MSC in both aspirates. MSCs of the bone marrow were, thanks to the studies of Arnold Caplan, and the fact that the bone marrow was well known as the progenitor organ of hematopoietic stem cells, the first to be studied, isolated and characterized, but in short, adipose tissue has shown to possess similar regenerative characteristics with some obvious advantages such as abundance, even greater technical ease of harvesting and the much greater quantity of MSCs obtainable

https://scholar.google.com/scholar?hl=en&as_sdt=0,5&qsp=2&q=comparison+of+bone+marrow+%22adipose+tissue%22&qst=br

The biological and clinical action of MSCs is mainly mediated by their secretome which includes exosomes and proteins as well as RNAs, so much so that Caplan himself has renamed them as Medicinal Signaling Cell with a particularly important biological action in ordinary maintenance tissue and response to trauma [2]. MSCs derive from the pericytes of the capillaries of any tissue: a trauma to the capillary wall causes the release in the tissue interstitium of the pericyte (PRP clinical effect is explained by the stimulation of the detachment of the pericytes but has no effect on the vascular density) that in short (minutes / hours) is transformed into MSC and secretes numerous cytokines that interfere with inflammation and in particular with macrophages, increasing their anti-inflammatory action; only after a couple of weeks many more specific cytokines are secreted with antibiotic, antifibrotic, angiogenic and last but not least pain relieving action [3]. This field of medicine is booming with over 8500 literature entries in the last year alone

https://scholar.google.com/scholar?as_ylo=2020&q=msc+and+re+generation+mechanism&hl=en&as_sdt=0,5

It is not clear what is the density of MSC necessary to obtain a certain biological action, however the excellent clinical action on symptomatic osteoarthritis of BMAC (concentrated bone marrow aspirate-about 20,000 MSC/cc) was comparable to that of lipogems at one year whose average content is decidedly higher (about 1000000 MSC/cc). In any case, while in the bone marrow it is easier to count MSCs directly; in adipose tissue, direct counting is almost impossible as most of the MSCs are trapped in the microvessels present within the tissue microclusters. The count of MSCs in adipose tissue is possible only after an enzymatic or mechanical separation process that causes the complete (enzymatic) or semi-complete (mechanical) destruction of the adipose tissue and its original structure to obtain a mix of cells called vasculostromal fraction or SVF (stromal vascular fraction), a preparation widely used in clinical and laboratory research but still subject to significant regulatory problems in common clinical practice. The SVF obtained from 1cc of adipose tissue contains a number of MSCs approximately 500 times greater than in 1cc of unconcentrated bone marrow aspirate, but as we have seen there is a poor correlation between the number of MSCs and biological / clinical action as it seems to be quite similar in clinical trials [4].

Medullary Aspirate, Lipoaspirate, MFAT, SVF and Expanded MSC

From the above it is clear that LIPOGEMS is absolutely not a device for mechanically isolating MSCs as many mistakenly believe [5-7]. In fact, MFAT has nothing to do with the SVF that results from the enzymatic or mechanical disintegration of the lipoaspirate with complete destruction of the original tissue structure in order to obtain the possibility of isolating and possibly cultivating the MSCs. Lipogems is the adipose tissue obtained by a significant reduction in size and washing of a lipoaspirate with clusters of about 3 mm. It is critically important to understand that it is still adipose tissue with fully preserved clusters of about 0.3/0.5 mm and what is remarkable is that the surface contains many microvessels and it is hugely exposed (about 6000 times) if we compare to the original lipoaspirate [8]. It is very important to understand the differences in the biological and clinical action of the different regenerative preparations: in fact, it is not absolutely certain, as also mentioned previously, that a greater number of MSCs results in a more marked biological action, both as regards the secretome or the exosomes obtained in vitro, and in the in vivo measurement in animal studies of the final biological action [9,10].

https://scholar.google.com/scholar?q=enzymatic+mechanical+adipose+tissue+processing+lipogems&hl=en&as_sdt=0%2C5&as_ylo=2015&as_yhi=

The Lipogems® Device and Because MFAT (Lipogems) is Structurally Identical to the Lipoaspirate but with More Efficient Biological Properties, so Much so that it is in Fact a Natural Implantable Bioreactor

The Lipogems® system (Figure 3) was initially designed and patented to optimize the clinical results of lipofilling: the adipose tissue is aspirated by small disposable cannulas (14G) with multiple oval holes of 2x1 mm (smaller holes slow down the procedure and create more damage to the aspirated fat). The aspirated adipose tissue, with cluster size of about 3 mm, is inserted into a completely closed device that washes the fat from blood, oily and inflammatory residues while the size of the adipose cluster is gradually reduced to about 0.3 mm, through sharp filters, and only by mechanical forces. Correct processing is critical, <https://www.lipogems.com/lipogems-tutorial> and in particular the absence of air so that the volumetric reduction is performed by exploiting the protection of the physiological pressure which avoids the destruction of adipocytes by bursting while maintaining the structural integrity of the adipose tissue. The marbles inside do NOT have the function of fragmenting the adipose tissue, but only to allow a good cleaning against the gravity of the oily / blood emulsion and to disperse the tissue so that it can be passed easily

through the second cutting filter. It is important to shake for no less than 20 seconds and no more than 90 seconds in total, always checking the absence of air inside the device.

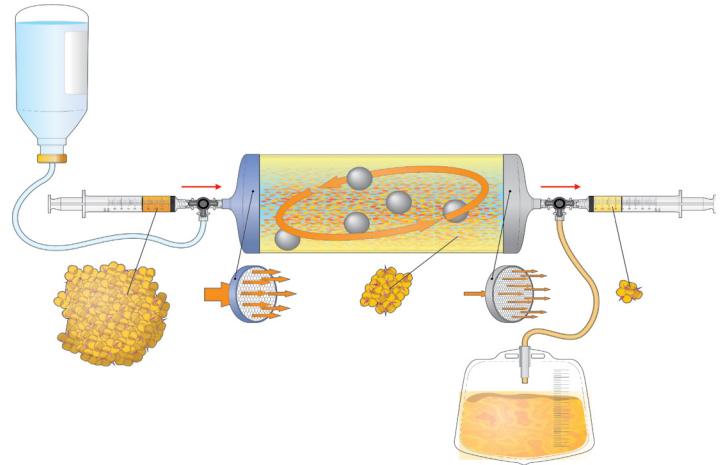



Figure 3: The Lipogems® system.

The Lipogems® product (Figure 4), i.e. the fragment of tissue washed from oily impurities and dead cells and perfectly intact from the structural point of view of about 300 microns (0.3 mm) in diameter, represents in all respects a natural implantable bioreactor that incorporates the main elements for a perfect natural regenerative response: the scaffold (the structure perfectly integrates also from the microvascular point of view of the adipose tissue), the cells (in particular pericytes/MSC) and the growth factors (secreted cytokines are initially stimulated by mechanical trauma and subsequently are specifically secreted depending by the environment in which lipogems cluster are implanted). The local injection of such a tissue is a living graft, which easily integrates into the recipient tissue (the small size and the respect for the structure make it the ideal graft facilitating rapid passive and active revascularization) and can function for a long time substantially improving the natural local healing potential. In this regard it is very interesting to note how in each of us the recovery following a trauma, or a disease is very different depending on the vascular micro density of the tissues [11,12].

https://scholar.google.com/scholar?hl=en&as_sdt=0%2C5&q=healing+capacity+vascular+density&btnG=

which varies inversely proportional to age and general conditions (for example in diabetic subjects there is always an early decrease in vascular micro density, as well as in the tissue of the elderly compared to the child).



- 100% Live adipose tissue
- IDEAL SIZE to obtain GRAFTING
- preserved cell and tissue microarchitecture essential to help healing.
- Reduced quantity of impurities that cause inflammation (blood and oil)

Figure 4: The Lipogems® product.

The reduction of the lipoaspirate from 3mm to 0.3mm in diameter causes an enormous increase in the number of grafted pieces: from each original fragment, in fact, about 1000 pieces are formed perfectly intact and covered on the surface by capillaries. The surface has increased even more (up to about 6000 times) thus exposing a very large amount of capillaries and consequently of pericytes ready to function in a completely natural way. Furthermore, it has been seen that MFAT actively produces microcapillaries in vitro in a similar way to the aorta ring and induces a neovasculogenesis also in the recipient tissue (Figure 5).

https://scholar.google.ch/scholar?hl=it&as_sdt=0%2C5&as_vis=1&q=lipogems+vasculogenesis&btnG=

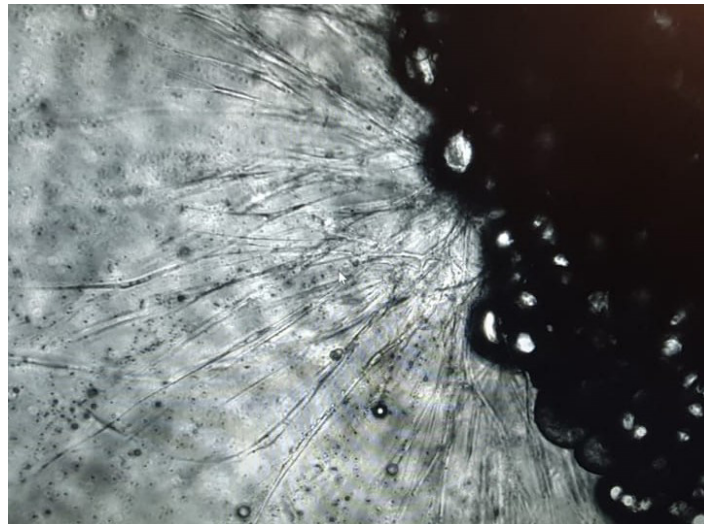


Figure 5: Vessel-like structures sprouting from lipogems cluster in culture.

From the above it is understandable that one of the main mechanisms by which MFAT increases the healing capacity of the tissues is to stably increase the vascular density, resulting in a real tissue rejuvenation, as is evident clinically and by examining the histology of the tissues treated in gynecological and aesthetic applications even years after application [12-14]. The transplantation of microfracture adipose tissue according to the lipogems technique, which from now on we will shorten as MFAT, has been used in a safe and effective way in thousands of patients, in human and veterinary medicine and in many different clinical applications in over 8 years [15-33].

https://scholar.google.ch/scholar?hl=it&as_sdt=0%2C5&as_vis=1&q=lipogems+mfat&btnG=

The Regulatory Framework

The LIPOGEMS device received FDA authorization in 2014 as a class II medical device for the processing of autologous adipose tissue. According to the FDA, Lipogems® can be defined as a tissue: (1) autologous; 2) minimally manipulated; 3) intended for homologous use (structural use); 4) free of enzymes; 5) not dependent on the metabolic activity of cells for its primary function; 6) used in the same surgical procedure and (7) not combined with anything other than saline. In 2016, the FDA issued a second authorization to process adipose tissue to be used in various surgical applications including arthroscopy: this means that the MFAT can be safely used by the surgeon as an autologous transplant for musculoskeletal applications and within any joint. However, because it is not required by the regulatory system of medical devices unlike drugs, there is no specific therapeutic indication of the lipogems device, for example for osteoarthritis; moreover, MFAT is considered by the FDA and EMA to all intents and purposes an autologous transplant and not a biological drug and the therapeutic indications are regulated by the rules of good medical-surgical practice, that is, by the indications derived from the results reported in clinical trials where the product lipogems/MFAT it was found to be safe and particularly effective.

Clinical Applications of Lipogems

In general surgery, Lipogems® has been used as a valid approach for the treatment of fecal incontinence and anal fistulas, showing impressive morphological regeneration and long-term recovery of muscle and neurological function even in irradiated medium.

https://scholar.google.com/scholar?hl=en&as_sdt=0%2C5&as_ylo=2015&q=lipogems+and+mfat+in+colorectal+fistula+&btnG=

In orthopedic surgery and better in the musculoskeletal field, most patients with degenerative and inflammatory joint diseases can benefit from intra and peri-articular Lipogems with over 140 continuously updated clinical papers. https://scholar.google.com/scholar?q=lipogems+and+mfat+in+orthopedics&hl=en&as_sdt=0%2C5&as_ylo=2015&as_yhi=

After injecting a variable amount of Lipogems® (0.2-12 ml depending on the joint), patients generally reported a brilliant immediate improvement in symptoms but above all a long-term resolution of pain. In most cases, patients previously candidates for surgery due to the severity of the degeneration no longer needed it due to complete or substantial resolution of their symptoms. The preoperative and postoperative radiographic and MRI comparison has often shown a possible regeneration of the articular cartilage and an enlargement of the articular space from 6 to 18 months after treatment; however the clinical improvement is usually more evident than the radiographic one and sometimes there is no correlation at all between radiologic and clinical findings. Additionally, the orthopedic use of Lipogems® has also proved rewarding to aid repair in injured or degenerated ligaments or tendons, in meniscal tears, around surgical wounds, in and around

osteotomy spaces or in delayed bone union.

These results have been confirmed in Veterinary Medicine where Lipogems is becoming an important regenerative therapy moreover in dogs and horses but also in exotic animals

https://scholar.google.com/scholar?q=lipogems+and+mfat+in+veterinary+medicine&hl=en&as_sdt=0%2C5&as_ylo=2012&as_yhi=

In reconstructive plastic surgery, Lipogems® helps the healing of chronic ulceration of the legs and feet, especially in diabetic patients, with very encouraging results

https://scholar.google.com/scholar?hl=it&as_sdt=0%2C5&q=lipogems+mfat+diabetic+foot+ulcers&btnG=

Cosmetic surgery is an ever-growing field of application and Lipogems® is used alone or in association with traditional surgical techniques such as lifting, blepharoplasty, breast augmentation and others where the impression is that Lipogems® improves and accelerates the times and the quality of healing. Optimal results were obtained in the periorbital area and in orthognathic surgery. After surgery, patients do not complain of pain, swelling or bruising and are generally very satisfied with a continuous improvement in skin texture and elasticity particularly evident from 9 to 18 postoperative months, tracing quite faithfully what happens in other surgical fields where it is observed. a powerful early anti-inflammatory effect (hours / days) followed by a late and prolonged regenerative effect (months / years)

https://scholar.google.com/scholar?hl=en&as_sdt=0%2C5&as_ylo=2012&q=lipogems+and+mfat+in+aesthetic+and+orthognatic+surgery&btnG=

Overview of The Clinical Experience of Image Regenerative Clinic in 1000 Consecutive Patients Treated with Lipogems Technique over a Ten Year Period (2011-2021)

Image Regenerative Clinic in Milano has been the main training center of surgeons for 10 years in Lipogems applications. We choose to report the clinical experience on a total of 1000 consecutive devices used on 1000 consecutive patients in the period from 6th february 2015 (when a consistent clinical protocol was approved) to 14th december 2019 to have at least 2 years of follow up. The charts were examined in january 2022 by one the doctor of the clinic (D.S.) not directly involved in the surgical treatments. Multiple procedures with lipogems on the same patient are the rule in Image regenerative Clinic with only a minority (24,9%) treating a single area such as a single joint (4,1%) or doing only lipogems beauty (meaning face and/or hands 8,2%) or lipogems gynecology (meaning postmenopausal vaginal 6,2% or dispareunia 0,4% or lichen sclerosus 1%) or lipogems surgery (meaning fecal incontinence 0,8% or fistula 0,9% or other 0,3%). Treating multiple joints, as a philosophical approach stressing prevention, has become the standard with an avarage of 4,57% joints treated per patients (2975 joints in 649 patients), quite interestingly more than half of this group (349/649 patients) did a combo of ortho and

beauty lipogems treatment; 102 patients did combined non-ortho procedure which the most common combo was gynecology and lipogems beauty (98 patients). Almost all the patients (998/1000) were followed up at least by phone calls for the first 6 months and most (922) for at least 24 months.

A very simple questionnaire was done with three grade of satisfaction (high, medium, low). At six months we had 71% high, 21% medium and 8% low; at one year 75% high 19% medium and 11% low and at 2 years 70% high 17% medium and 13% low. These data shows that , once the lipogems procedure is well explained to the patient from a biological point of view, the patient himself is willing to do as many sites as possible (providing the cost is only minimally increased). This approach proved very usefull in increasing the overall short and long term high and medium satisfaction to nearly 90% with most patiens referring other patients for some regenerative treatment.

Future Directions

Lipogems can be a source of cultivated Mesenchymal Stem Cells that show a better quality that the one obtained by mechanical dissociation both as differentiation potential and looking to the secretome. Besides in vivo Lipogems performs better in cartilage regeneration than both svf and culture expanded MSC [34,35] (Figure 6). Lipogems has also been recently accepted by the regional tissue bank in Emilia Romagna region (Italy) as an autologous source of adipose tissue suitable for long term banking for regenerative procedures or mixing with other cryopreserved tissues. Finally Lipogems appears to be a perfect scaffold for local drug delivery which can be useful mainly for treatment of local cancer

https://scholar.google.com/scholar?hl=it&as_sdt=0%2C5&q=lipogems+drug+delivery+cancer&btnG=

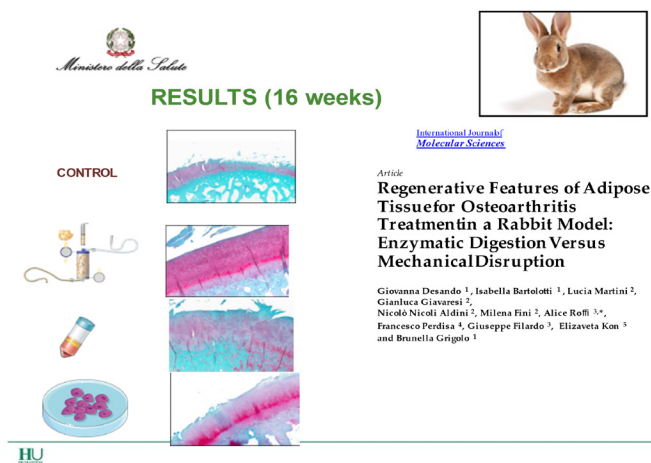

Figure 6: Experimental model on rabbit osteoarthritis where it is clear that there is absolutely no correlation between the number of MSCs and regenerative capacity since experimentally the quantitative differences in cartilage regeneration between MFAT,

SVF and cultured MSC are negligible, indeed, observing the histology it is noted that the neo-cartilage derived from MFAT is structurally more normal respecting all the natural maturation phases [35].

Conclusions

Adipose tissue is the ideal source but above all for the practical clinical use of the Mesenchymal Stem Cells contained therein since (i) it is easily accessible and collected through a minimally invasive surgical procedure, (ii) it can be found in quantity sufficient in most people and (iii) ensures an adequate amount of progenitor cells with good viability and minimally age-related differentiating potential. Lipogems® technology naturally optimizes the healing and regenerative properties of adipose tissue by reducing the size of the adipose tissue clusters, maintaining their structural and functional integrity without using enzymes, additives or centrifugations, but relying on the use of mild mechanical forces and exploiting the protection offered by saline which fills a completely closed system in the absence of air. Numerous randomized clinical trials are currently underway in various application fields to develop innovative therapeutic strategies and clinical protocols using various products derived from adipose tissue; We are convinced that a critical comparison between the different products is essential to identify which is the ideal preparation with the most homogeneous characteristics in order to be able to strategically concentrate clinical research efforts in this extremely promising field.

References

1. Tremolada C, Palmieri G, Ricordi C (2010) Adipocyte transplantation and stem cells: plastic surgery meets regenerative medicine. Cell Transplant 19: 1217-1223.
2. Caplan AI, Correa D (2011) PDGF in bone formation and regeneration: new insights into a novel mechanism involving MSCs. Journal of Orthopaedic Research 12: 1795-1803.
3. Caplan AI, Correa D (2011) The MSC: an injury drugstore. Cell Stem Cell 9: 11-15.
4. Mautner K, Bowers R, Easley K, Fausel Z, Robinson R (2019) Functional Outcomes Following Microfragmented Adipose Tissue Versus Bone Marrow Aspirate Concentrate Injections for Symptomatic Knee Osteoarthritis. STEM CELLS Translational Medicine 8: 1149-1156.
5. Copcu HE, Oztan S (2021) Not Stromal Vascular Fraction (SVF) or Nanofat, but Total Stromal-Cells (TOST): A New Definition. Systemic Review of Mechanical Stromal-Cell Extraction Techniques. Tissue Eng Regen Med 18: 25-36.
6. Aronowitz JA, Lockhart RA, Hakakian CS (2015) Mechanical versus enzymatic isolation of stromal vascular fraction cells from adipose tissue. Springer Plus 4: 713.
7. Trivisonno A (2019) Intraoperative Strategies for Minimal Manipulation of Autologous Adipose Tissue for Cell and Tissue Based Therapies: Concise Review. Stem cells translational medicine 8: 1265-1271.
8. Tremolada C, Colombo V, Ventura C (2016) Adipose Tissue and Mesenchymal Stem Cells: State of the Art and Lipogems® Technology Development. Curr Stem Cell Rep 2: 304-312.

9. Tengjing Xu , Xinning Yu, Quanming Yang, Xiaonan Liu, Jinghua Fang, et al. (2019) Autologous Micro-Fragmented Adipose Tissue as Stem Cell-Based Natural Scaffold for Cartilage Defect Repair. *Cell Transplantation* 28: 1709-1720.
10. Vezzani B (2018) Higher pericyte content and secretory activity of microfragmented human adipose tissue compared to enzymatically derived stromal vascular fraction. *Stem cells translational medicine* 7: 876-886.
11. Bouglé A, Rocheteau P, Briand D, Hardy D, Verdonk F, et al. (2019) Beneficial role of adipose-derived mesenchymal stem cells from microfragmented fat in a murine model of duchenne muscular dystrophy. *Muscle & nerve* 60: 328-335.
12. Mastrangelo AN, Haus BM, Vavken P, Palmer MP, Machan JT, et al. (2010) Murray Immature animals have higher cellular density in the healing anterior cruciate ligament than adolescent or adult animals. *J Orthop Res* 28:1100-1106.
13. Filardo G, Tschon M, Perdisa F, Brogini S, Cavallo C, et al. (2021) Micro-fragmentation is a valid alternative to cell expansion and enzymatic digestion of adipose tissue for the treatment of knee osteoarthritis: A comparative preclinical study. *Knee Surgery, Sports Traumatology, Arthroscopy* 19: 1-9.
14. Casarotti GA, P Chiodera, C Tremolada (2018) Menopause: new frontiers in the treatment of urogenital atrophy. *Eur Rev Med Pharmacol Sci* 22: 567-574.
15. Tremolada CM, Allegri, M Slevin (2019) Mesenchymal stromal cells and micro fragmented adipose tissue: new horizons of effectiveness of lipogems. *J Stem Cell Res Dev Ther* 5: 017.
16. Gobbi A, Dallo I, Rogers C (2021) Two-year clinical outcomes of autologous microfragmented adipose tissue in elderly patients with knee osteoarthritis: a multi-centric, international study. *International Orthopaedics (SICOT)* 45: 1179-1188.
17. Hogaboom, Nathan (2021) A pilot study to evaluate micro-fragmented adipose tissue injection under ultrasound guidance for the treatment of refractory rotator cuff disease in wheelchair users with spinal cord injury. *The Journal of Spinal Cord Medicine* 2021: 1-10.
18. Zeira, Offer (2018) Intra-articular administration of autologous micro-fragmented adipose tissue in dogs with spontaneous osteoarthritis: Safety, feasibility, and clinical outcomes. *Stem cells translational medicine* 7: 819-828.
19. Lavagnolo, Umberto (2021) Lipoaspirate processing for the treatment of knee osteoarthritis: a review of clinical evidences. *Biomedicine & Pharmacotherapy* 142: 111997.
20. Heidari, Nima (2021) Microfragmented Adipose Tissue Injection (MFAT) May Be a Solution to the Rationing of Total Knee Replacement: A Prospective, Gender-Bias Mitigated, Reproducible Analysis at Two Years. *Stem Cells International* 2021.
21. Malanga, Gerard A (2021) Clinical evaluation of micro-fragmented adipose tissue as a treatment option for patients with meniscus tears with osteoarthritis: a prospective pilot study. *International Orthopaedics* 45: 473-480.
22. Zhou, Xiaopeng (2020) Micro fragmented adipose tissue promotes the matrix synthesis function of nucleus pulposus cells and regenerates degenerated intervertebral disc in a pig model. *Cell transplantation* 29: 0963689720905798.
23. Malanga, Gerard A, Sean Bermanian (2019) Microfragmented adipose injections in the treatment of knee osteoarthritis. *Journal of Clinical Orthopaedics & Trauma* 10: 46-48.
24. Robinson DM (2020) Outcomes after Micronized Fat Adipose Transfer for Glenohumeral Joint Arthritis and Rotator Cuff Pathology: a Case Series of 18 Shoulders. *Muscles, Ligaments & Tendons Journal (MLTJ)* 10.
25. Giori A (2015) Recovery of function in anal incontinence after micro-fragmented fat graft (Lipogems®) injection: two years follow up of the first 5 cases. *CellR4* 3: e1544.
26. Hudetz, Damir (2017) The effect of intra-articular injection of autologous microfragmented fat tissue on proteoglycan synthesis in patients with knee osteoarthritis. *Genes* 8: 270.
27. Borić, Igor (2019) A 24-month follow-up study of the effect of intra-articular injection of autologous microfragmented fat tissue on proteoglycan synthesis in patients with knee osteoarthritis. *Genes* 10: 1051.
28. Naldini G (2018) Micro-fragmented adipose tissue injection for the treatment of complex anal fistula: a pilot study accessing safety and feasibility. *Techniques in coloproctology* 22: 107-113.
29. Casarotti G, Tremolada C (2020) A new treatment of genito-urinary post-menopausal atrophy with autologous micro-fragmented fat tissue: a thirty-six months follow up case series. *European Review for Medical and Pharmacological Sciences* 24: 7420-7426.
30. Lonardi, Roberto (2019) Autologous micro-fragmented adipose tissue for the treatment of diabetic foot minor amputations: a randomized controlled single-center clinical trial (MiFrAADiF). *Stem cell research & therapy* 10: 1-9.
31. Hudetz, Damir (2019) Early results of intra-articular micro-fragmented lipoaspirate treatment in patients with late stages knee osteoarthritis: A prospective study. *Croatian medical journal* 60: 227-236.
32. Laureti, Silvio (2020) Refractory complex Crohn's perianal fistulas: a role for autologous microfragmented adipose tissue injection. *Inflammatory bowel diseases* 26: 321-330.
33. Striano RD, Battista V, Bilboo N (2017) Non-responding knee pain with osteoarthritis, meniscus and ligament tears treated with ultrasound guided autologous, micro-fragmented and minimally manipulated adipose tissue. *Open Journal of Regenerative Medicine* 6: 17-26.
34. Mikkelsen RK (2021) Treatment of osteoarthritis with autologous, micro-fragmented adipose tissue: a study protocol for a randomized controlled trial. *Trials* 22: 1-11.
35. Desando G (2019) Regenerative features of adipose tissue for osteoarthritis treatment in a rabbit model: enzymatic digestion versus mechanical disruption. *International journal of molecular sciences* 20: 2636.